

X-Rays Show Structural Changes After Biomodulator Microcurrent Treatment

Introduction

Jarrah Ali Al-Tubaikh, MD – specializes in radiological diagnostics of rare disorders. He is a member of the German Board of Radiology and currently works in the Radiology Department, Sabah Hospital, Kuwait City, Kuwait.

Kuwait offers a sophisticated healthcare system to its residents, with highly trained specialists. Despite best medical practices and state-of-the-art interventions by physicians, many of these patients continue to suffer from excruciating pain. Since Dr. Al-Tubaikh was introduced to the Tennant Biomodulator® medical device and protocols of Jerry Tennant, MD, MD(H), PScD of Colleyville, Texas, Dr. Al-Tubaikh has significantly improved or eliminated ongoing pain in these patients.

Background

As a radiologist, Dr. Al-Tubaikh assesses many patients who are referred to him to determine if the source of their pain can be identified by X-ray. A certain subset of those patients have been described to Dr. Al-Tubaikh as “hopeless” cases – physicians have run out of options available through the healthcare system.

Since learning of the Biomodulator microcurrent device for drug free, non-invasive pain relief, Dr. Al-Tubaikh has used it with patients and co-workers at his hospital as well as with friends, all of whom suffer with severe unresolved pain symptoms. In two cases, he used the Biomodulator with patients specifically referred to him because of severe back pain, as word of the “miracle” treatment spread. In each case, Dr. Tubaikh said he takes images before and after treatment to document changes that have taken place after Biomodulator treatment. “It is hard to argue against radiological images because the evidence is clear; it is not placebo anymore.”

Bowling Ball Syndrome – Sphenoid Malalignment

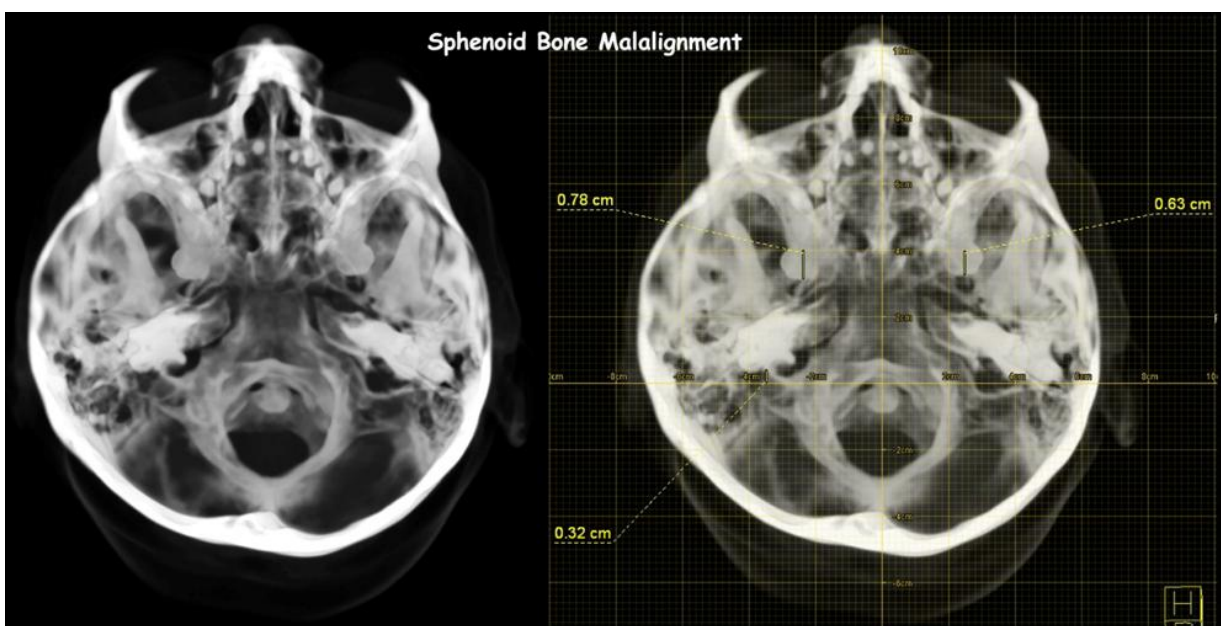
“Bowling Ball Syndrome” was first described by Robert Boyd, DO, who said that the head weighs about the same as a bowling ball. Because of its weight, the body will always put the upper cervical vertebra under the center of gravity of the head to keep the head upright. When the sphenoid bone is malaligned, the other cranial bones follow. This moves the center of gravity of the skull and causes the following compensating changes. It is theorized that these changes may cause pain, reduced functionality, and stress on a variety of physical systems:

- C1-C2 moved sideways causing persistent headaches and neck aches.
- Curvature of spine causing extrusion of disks.
- Migraine headaches.

X-Rays Show Structural Changes After Biomodulator Microcurrent Treatment

- Pelvis is rotated with pain in lower back.
- Rotated pelvis can cause joint issues on one hip-knee-ankle with disproportionate weight distribution.
- One shoulder is higher than the other.
- One scapula is higher than the other. This can lead to interscapular pain during driving, for instance.
- One ear canal is lower than the other.
- Obstruction of ocular canal can increase intraocular pressure and cause vision issues.
- Kinking of Eustachian tubes can lead to increased ear infections.
- Sinus and nasal obstructions, including snoring.
- Jaws may move, causing TMJ.
- Eyelid may droop (ptosis).
- “Locking” of the craniosacral pump causes the entire nervous system to have stagnant cerebrospinal fluid. Results in general decrease in healthy functions.

The computed tomographic (CT) image that follows shows the sphenoid bone malalignment that is indicative of the Bowling Ball Syndrome. The image clearly shows uneven petrous (Ear) bones position compared to the sphenoid bone anteriorly; also, notice the uneven shape of the occipital bone (bone of the back of the head). In radiology, a general rule in plain radiography interpretation is to consider the body to have symmetric, mirror-image structures, and any asymmetry can result from misshaped bones or spine. By treating Bowling Ball Syndrome with the Biomodulator ANS Reset protocol, using the Biomodulator Infinity mode to stimulate the sternocleido mastoid, the sphenoid bone is re-centered over the spinal column, restoring symmetry and mitigating pathologies caused, according to Boyd and others, by the malalignment.



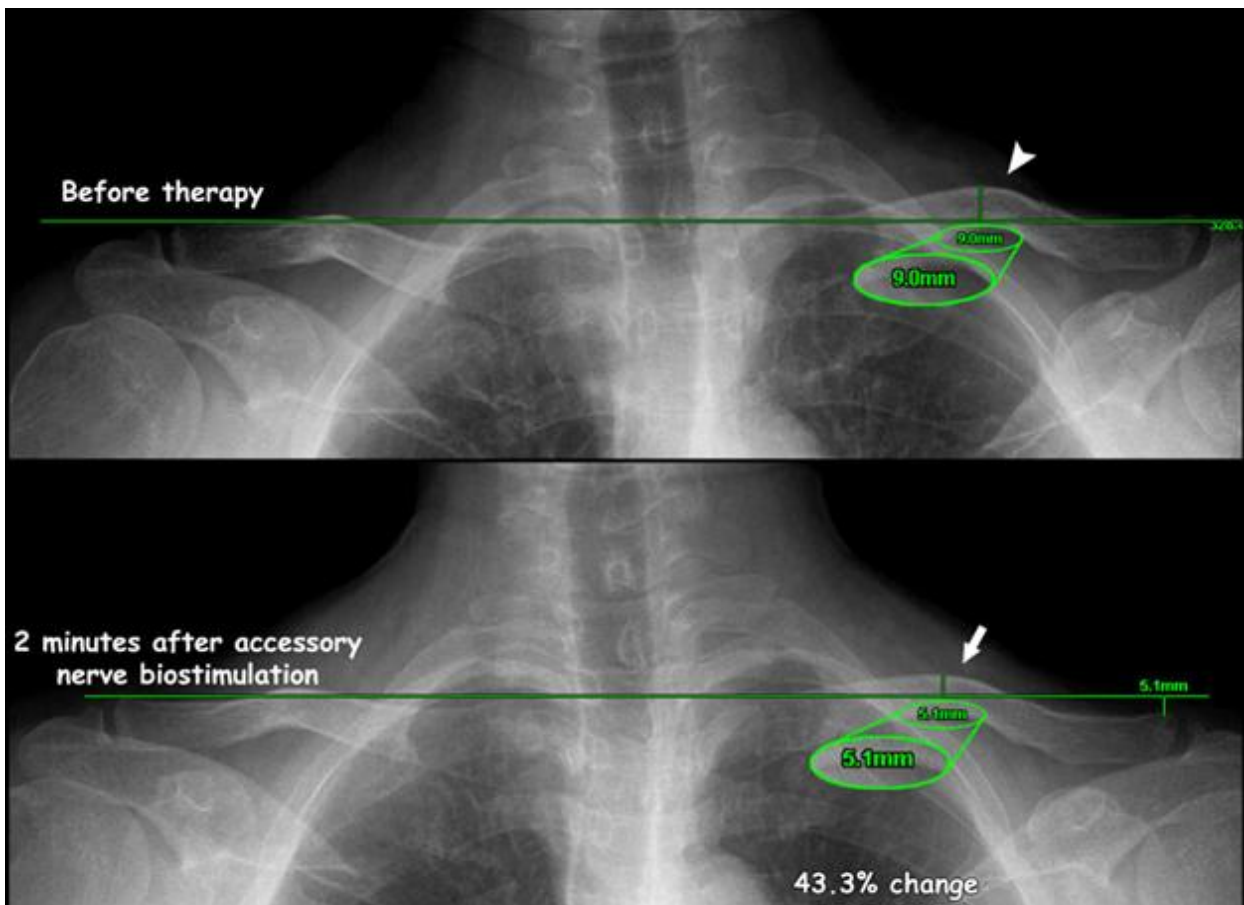
X-Rays Show Structural Changes After Biomodulator Microcurrent Treatment

This correction of the Bowling Ball Syndrome restores functionality of the autonomic nervous system (ANS), which is comprised of the sympathetic nervous system (most commonly referred to as the fight-or-flight response) and the parasympathetic nervous system (which aids in the control of most of the body's organs). Stress — as in the flight-or-flight response — is thought to counteract the parasympathetic system, which generally works to promote maintenance of the body at rest, digestion and immune system. The comprehensive functions of both the parasympathetic and sympathetic nervous systems are not so straightforward, but this is a useful rule of thumb.⁶

It can be extrapolated that based on Boyd's research, correcting for the "Bowling Ball Syndrome" may improve a range of conditions. Dr. Al-Tubaikh's diagnostic images taken before ANS Reset treatment appear to show symptoms of Bowling Ball Syndrome. Following 2 minutes of ANS reset, images show realignment of the spine as reflected in four cases that follow.

Case 1: 43% change in malposition

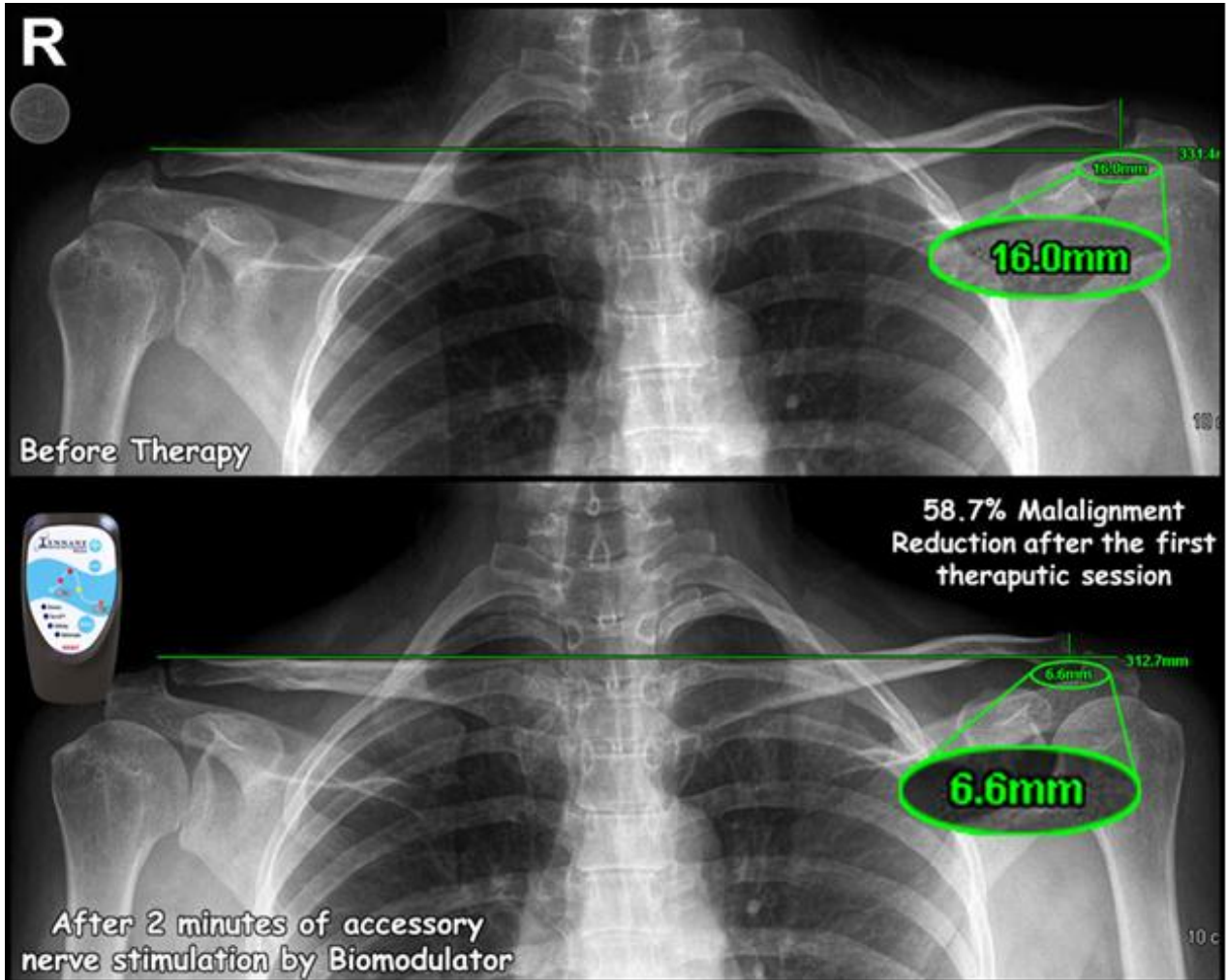
In one case (X-ray images below) the patient suffered from neck and left shoulder pain. "Her initial X-ray shows a left clavicular mild malposition," Dr. Al-Tubaikh's said. "I gave her two minutes cervical bio-stimulation with the Biomodulator set at Infinity mode at a comfortable power level." He repeated the X-ray, with results as shown, with a 43 percent change in malposition.



X-Rays Show Structural Changes After Biomodulator Microcurrent Treatment

Case 2: 59% change in malposition

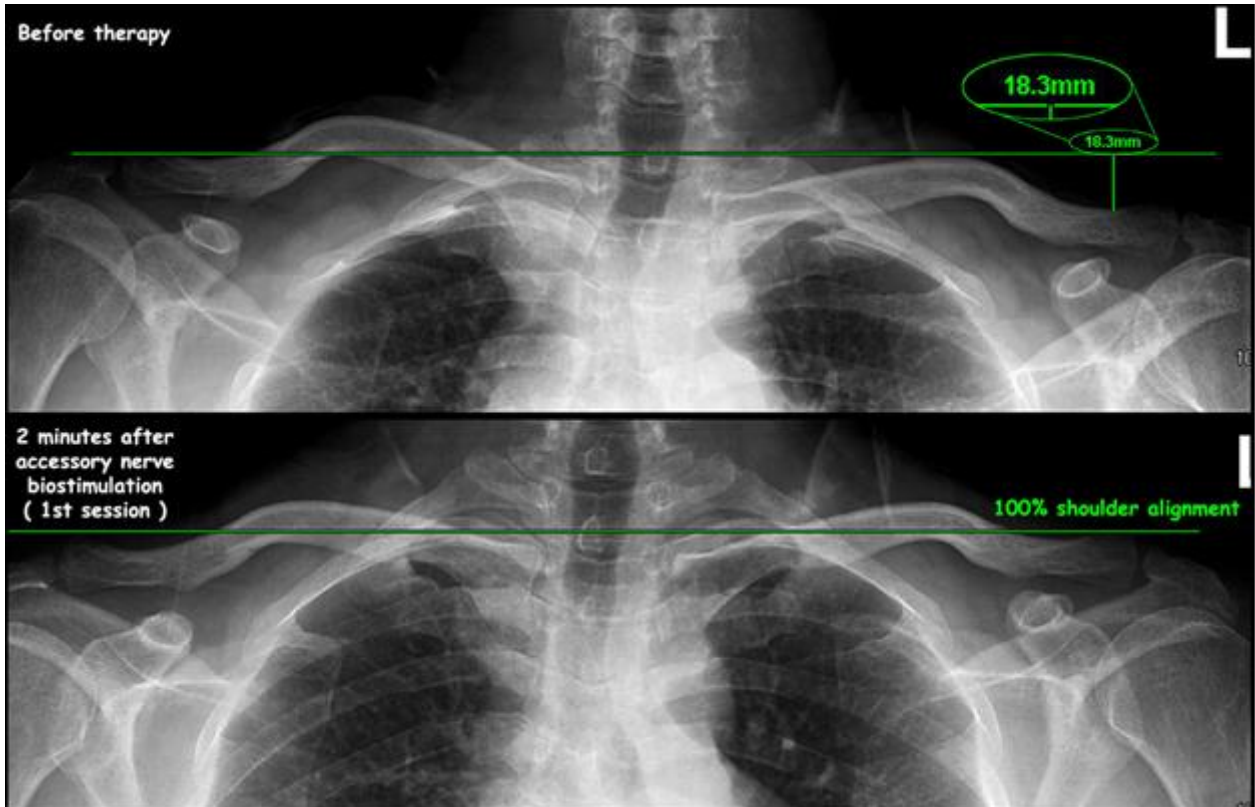
In another case, a patient with severe shoulder and back pain arrived. "X-rays showed that her shoulder is tilted to the left and her pelvis is tilted to the right," he said. "I used the Biomodulator on her neck for correcting the "Bowling Ball Syndrome," and I did X-rays after the first session. The radiographic findings are amazing."



X-Rays Show Structural Changes After Biomodulator Microcurrent Treatment

Case 3: 100% shoulder alignment

The before and after X-rays (below) show another of Dr. Al-Tubaikh's patients treated with the Tennant Biomodulator®. Additionally, comparing the "before" X-rays, to the images taken following the Biomodulator treatment, not only are the shoulders leveled but the spinal column is much straighter as well.



Various protocols have been used to treat this syndrome, although many are painful, invasive, and expensive. From his research, Dr. Tennant has applied the Biomodulator technology and developed a simple non-invasive, cranial-sacral adjustment technique that is cost effective and efficient. He recommends leading with this ANS (Autonomic Nerve System) Reset technique to treat the Bowling Ball Syndrome.

Dr. Al-Tubaikh continues to use the Biomodulator almost daily in the hospital and has the attention of many patients and doctors. Two additional case studies follow.

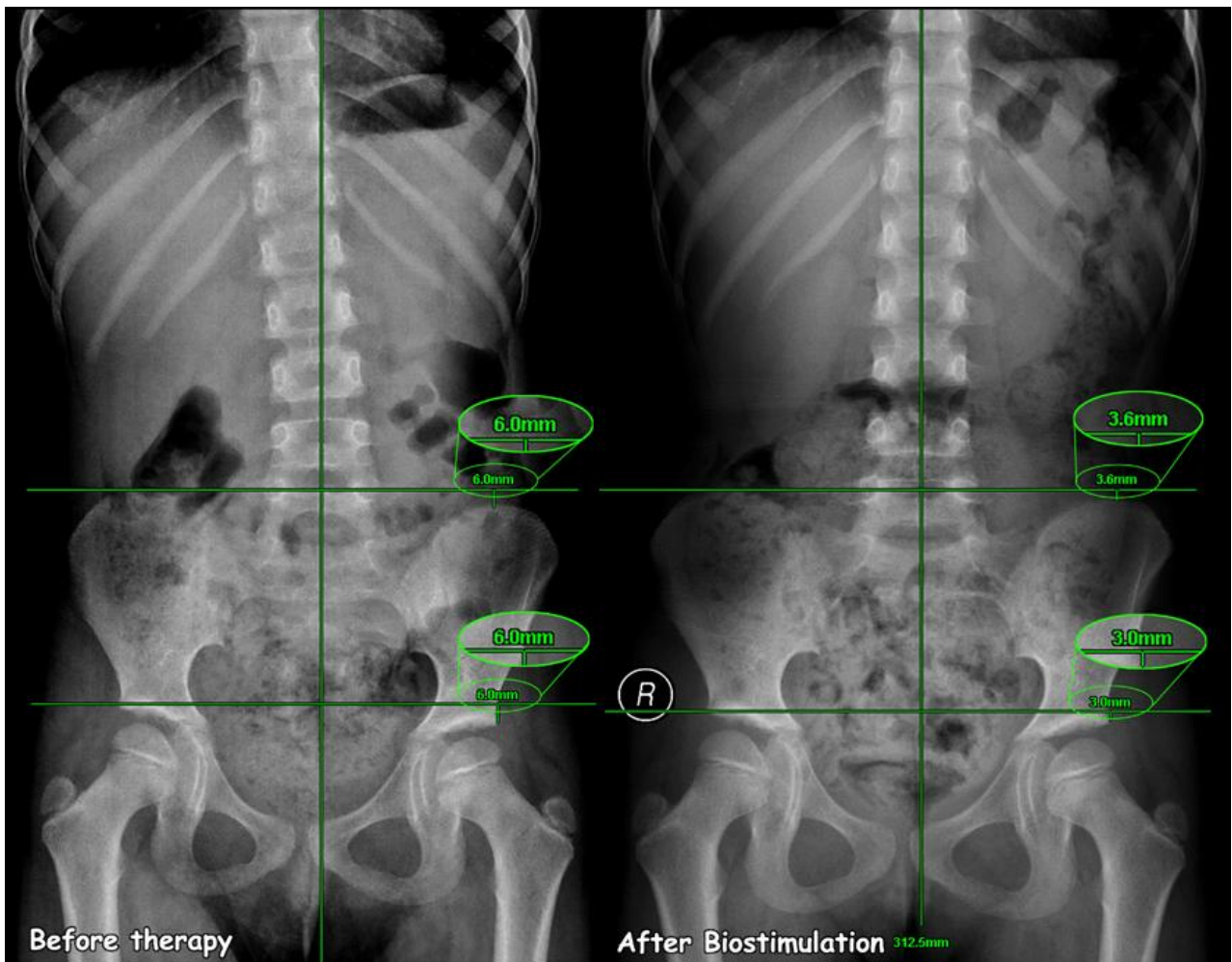
X-Rays Show Structural Changes After Biomodulator Microcurrent Treatment

Case 4: Spinal alignment correction and improved gait with ANS Reset (Bowling Ball) technique

A seven-year old female with an abnormal gait was referred by the genetic center for rare disorders consultation to Dr. Al-Tubaikh. She had been examined by the pediatric, genetic, and neurology departments for her abnormal gait. All examinations were normal including brain MRI and muscle electromyography (EMG). They sent her to Dr. Al-Tubaikh to exclude rare causes of gait abnormalities.

Her spine was imaged on standing position and revealed that her whole spine was shifted to the right side and her hip was shifted to the left as shown in the following before and after radiographic images.

Treating the Bowling Ball Syndrome with the Tennant Biomodulator®, on her neck, corrected her whole spinal alignment. Dr. Al-Tubaikh and his radiographers were amazed!! As her daughter started to move with a normal gait, the mother started to cry. The child was referred to a chiropractor for further treatments.

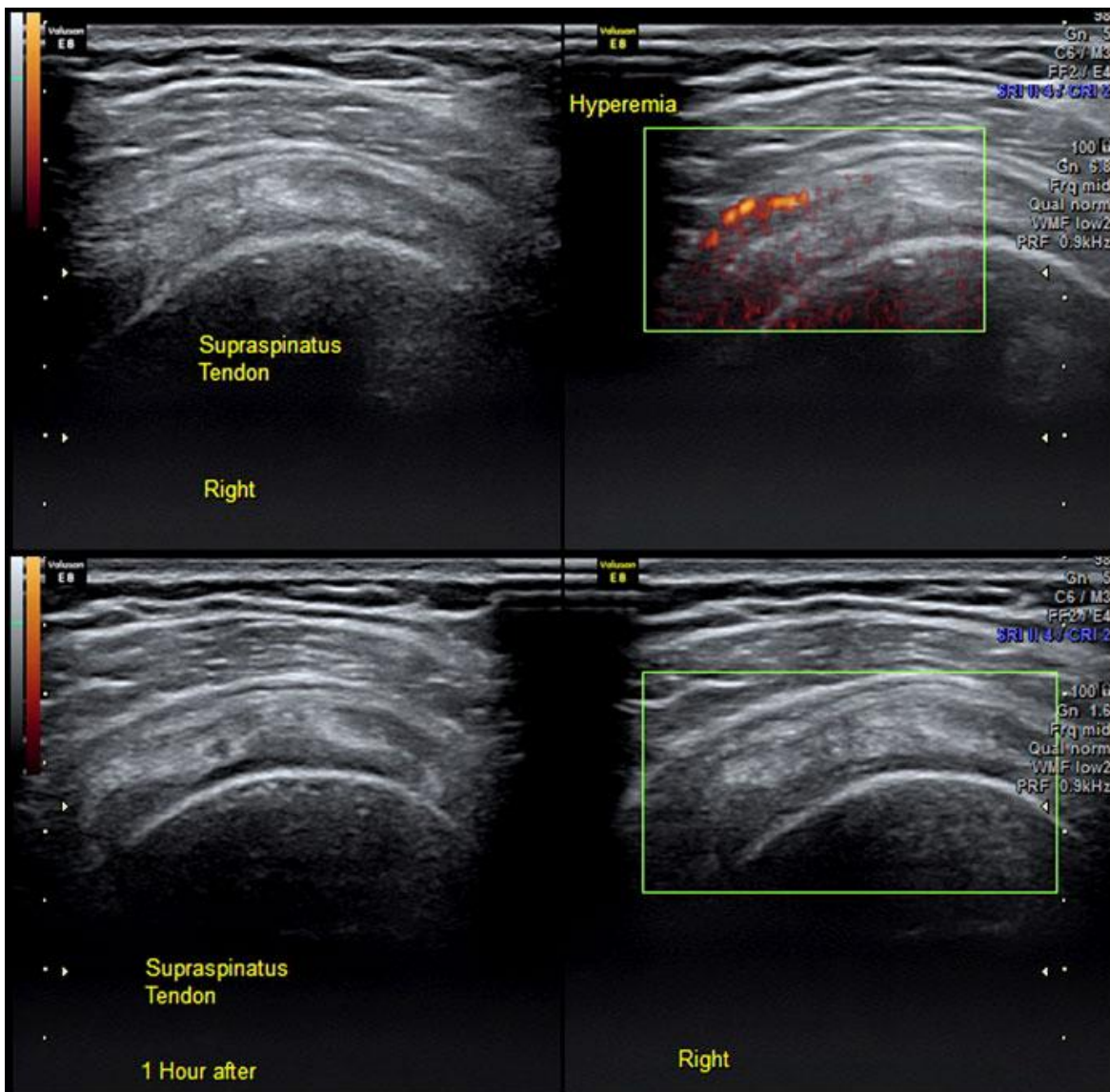


X-Rays Show Structural Changes After Biomodulator Microcurrent Treatment

Case 5: Reduction of inflammation

A 28 year old female patient had a history of rheumatoid arthritis with stiffness and extreme pain. The patient's shoulder was imaged by musculoskeletal ultrasound which revealed one of her shoulder tendons (Supraspinatus) was inflamed. Inflammation can be imaged by a technique called "Power Doppler," where the machine indicates the power of blood perfusion in the area, which is typically high for inflamed tissues (Hyperemia) and normal in normal tissues.

The inflammation will be seen as a red signal within the examined tissue; this signal is NOT seen in normal tissues. The Biomodulator's Infinity mode was applied with self-adhesive, conductive electrode pads on her shoulder for one hour. After the one-hour treatment, her shoulder was re-imaged revealing the hyperemia was gone indicating the inflammation had subsided. The patient reported being completely pain-free. While stiffness persisted, it had improved.



X-Rays Show Structural Changes After Biomodulator Microcurrent Treatment

Additional Case Summaries

Dr. Al-Tubaikh stated, “Really, I didn't expect such a profound effect on patients. I used the Biomodulator for three consecutive days at the hospital as word of mouth spread. In three days I have treated the following:

- A. One nurse with severe low back pain: She is seeing a chiropractor. I used the Biomodulator in Ten-8 mode for 7 minutes. She had complete relief of pain for more than 36 hours – the first time she’s been pain free for that long in years.
- B. A radiographer colleague had two disc protrusions in his neck, causing severe numbness in the hand for the past six months. I used the Biomodulator for 2 minutes in Ten-8™ mode in the disc area and 3 minutes on the hand. The result was approximately a 50% decrease in numbness. He asked for additional treatments in the future.
- C. A patient with chronic abdominal pain due to an ugly abdominal scar that had entrapped the nerves. She has had surgery to relieve the pain with partial improvement. The patient presented with severe pain. I used the Biomodulator to treat her. She was pain-free in three minutes and called it “a magic trick.”

Tennant Biomodulator® Technology

The Tennant Biomodulator® device uses specific, patented microcurrent technology to encourage the body to use its own resources to produce a healing outcome. Microcurrent has been shown^{1,2,3,4} repeatedly to reduce pain and improve a variety of health conditions.

While basic microcurrent technology has been around for more than 40 years, the Tennant Biomodulator® device uses a proprietary set of frequency patterns developed by Jerry Tennant, MD. These patterns or “modes” are delivered by patented microchips to produce very specific outcomes. These hand-held devices are FDA-cleared for the symptomatic relief and management of chronic, intractable pain and adjunctive treatment in the management of post-surgical and post-traumatic pain. The Tennant Biomodulator® uses different neural paths and a different wave form than a traditional TENS device. Rather than just masking pain, the Biomodulator targets C-fibers of the nervous system (most TENS devices work on the A- and B-fibers). C-fibers stimulate the production of neuropeptides and other regulatory peptides, which the body uses to heal itself.⁵

The Tennant Biomodulator® device produces unique, pulsed high-voltage, biphasic damped sinusoidal microcurrent electro-stimulation designed with Dr. Tennant’s frequency modes. These patented medical devices are manufactured in the USA by Avazzia, a Dallas-based company, exclusively for Senergy Medical Group, are US FDA cleared, and have earned the European CE mark.

X-Rays Show Structural Changes After Biomodulator Microcurrent Treatment

Conclusion

Dr. Al-Tubaikh has more cases that are too many for this introductory report. The differences of before and after images following the Bowling Ball Syndrome treatment using the Tennant Biomodulator® can be objectively measured via radiological images revealing measureable changes in the structure and tissue. Reduction of inflammation is shown by Doppler imaging of soft tissue injuries.

While Dr. Al-Tubaikh's results are anecdotal, his "before" and "after" X-rays show structural changes in the body after Biomodulator treatments. He reports patients received immediate decrease in pain. In some cases, Dr. Al-Tubaikh treated the Bowling Ball Syndrome; in others, he treated specific pain symptoms.

It is apparent that in the hands of a medical professional, the Biomodulator device provided significant pain relief for many patients with various issues (back pain, neck pain, numbness in the hand, etc.) In each of these cases, patients had depleted all "traditional" options for pain relief.

The value of the Biomodulator device as another tool in a physician's tool kit is apparent. It is especially valuable for physicians, chiropractors, physical and occupational therapists, and others who regularly encounter "difficult" or "impossible" cases where pain is a significant factor.

Dr. Jarrah Ali Al-Tubaikh is an internist, surgeon and currently well-regarded radiologist, trained in Germany (LMU Klinikum Grosshadern, Munich), now working at a Kuwaiti-government (Al-Sabah) hospital. He has several publications to his credit, including the texts *Congenital Diseases and Syndromes: An Illustrated Radiological Guide* (Springer; 2009) and *Internal Medicine: An Illustrated Radiological Guide* (Springer; 2010).

Dr. Jerry Tennant has authored several books including *Healing is Voltage*, *The Handbook* (2010, 3rd edition 2013) and *Healing is Voltage - Healing Eye Diseases* (2011), teaches courses, presents at medical conferences, and continues to see patients at the Tennant Institute for Integrative Medicine. Interviews can be seen on Healing Quest news magazine televised on PBS.

X-Rays Show Structural Changes After Biomodulator Microcurrent Treatment**Sources**

1. McMakin, CR (April 2004). "Microcurrent Therapy: A novel treatment method for chronic low back myofascial pain." *Journal of Bodywork and Movement Therapies* **8** (2): 143–153.
2. Park, RJ; Son, H; Kim, K et al. (2011). "The Effect of Microcurrent Electrical Stimulation on the Foot Blood Circulation and Pain of Diabetic Neuropathy." *Journal of Physical Therapy Science* **23** (3): 515–518.
3. Cho, MS; Park, RJ; Park, SH et al. (2007). "The effect of microcurrent-inducing shoes on fatigue and pain in middle-aged people with plantar fasciitis." *Journal of Physical Therapy Science* **19**(2): 165–170.
4. Lambert, MI; Marcus, P; Burgess T (April 2002). "Electro-membrane microcurrent therapy reduces signs and symptoms of muscle damage." *Med Sci Sports Exerc* **34** (4): 602–607.
5. Levine, JD; Fields, HL et al. (1993). "Peptides and the primary afferent nociceptor." *Journal of Neuroscience* **13**, 2273-2286.
6. Brodal, Per (2004). "The Central Nervous System: Structure and Function (3 ed.)." *Oxford University Press US*: 369-396.

Conflicts of Interest and Source of Funding: Jarrah Ali Al-Tubaikh, MD, Sabah Hospital in Kuwait City, Kuwait, provided the clinical facilities, radiological images, and patients reviewed in this report. No additional funding or additional resources from other sources were provided for this study. Jeanne Spreier, author of this publication, is independently contracted by Avazzia, Inc., Dallas, TX, USA. Avazzia developed and manufactures Tennant Biomodulator® microcurrent devices used in this report. Senergy Medical Group, 9901 Valley Ranch Parkway, Suite 1009, Irving, Texas, 75063 USA, www.senergy.us, 972-580-0545, is the exclusive worldwide distributor for the Tennant Biomodulator® medical device. Study-patients were not compensated for participation in the study.